



RESENTING CLINICAL SIGNS

History: New murmur. Pre-anesthetic evaluation (dental).

DATE

4/18/23

ECHOCARDIOGRAPHIC FINDINGS

2D, M-mode, and Doppler study.

PERFORMED BY:

Kelly Vazquez

Left atrial size is normal. The mitral valve is normal. Left ventricular wall thickness is normal. Left ventricular internal dimensions are normal. Left ventricular systolic function is hyperdynamic. The aorta and aortic valve are normal. Right atrial and right ventricular dimensions are normal. The tricuspid valve appears normal, though trace tricuspid regurgitation is present. The pulmonary artery and pulmonic valve are normal. No shunting lesions are visualized. No pericardial effusion or cardiac masses are seen.

INTERPRETED BY

Keith Blass, DVM,
MS, DACVIM
(Cardiology)

LA/Ao - 1.42
IVSd - 4.6 mm
LVPWd - 4.3 mm
LVIDd - 15.2 mm
LVIDs - 5.3 mm
FS - 65%
LVOT - 0.93 m/s
RVOT - 1.02 m/s

PATIENT

Pumpkin Temner

ASSESSMENT/RECOMMENDATIONS

Normal echocardiogram

SPECIES

Feline

This examination demonstrates no evidence of structural heart disease, as trace tricuspid regurgitation can be considered as normal physiologic variant. As such, Pumpkin's cardiovascular risk for general anesthesia appears to be low, and there are no contraindications to the use of any specific anesthetic agents.

BREED

DSH

No therapy is recommended based on this exam.

SEX

A recheck echocardiogram is recommended if the characteristics of Pumpkin's murmur change, or if other new physical exam and/or clinical abnormalities suggestive of the presence of cardiac dysfunction develop.

FS

AGE

8 y

WEIGHT

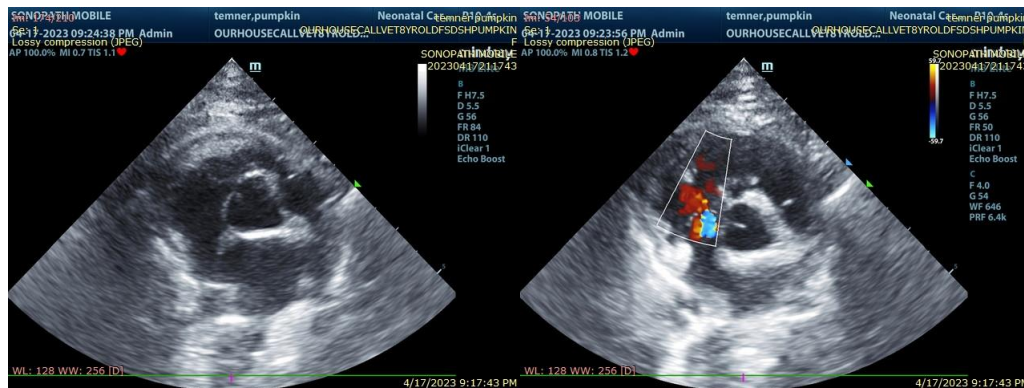
12.125 lb

HOSPITAL NAME

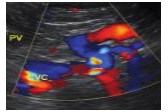
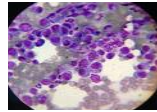
Our House Call Vet

REFERRING VET

Dr. Mazzola



The information and recommendations provided are based on the images presented by the referring veterinarian. No evaluation can be communicated regarding pathology that was not visible in the image/video clips provided.



Thank you for this referral. If the clinical or image interpretation does not parallel your findings or if I can be of any further assistance please contact me.

DATE

4/18/23

Keith Blass, DVM, MS, DACVIM (Cardiology)
KeithBlass@gmail.com
631-804-5754

PERFORMED BY:

Kelly Vazquez

INTERPRETED BY

Keith Blass, DVM,
MS, DACVIM
(Cardiology)

PATIENT

Pumpkin Temner

SPECIES

Feline

BREED

DSH

SEX

FS

AGE

8 y

WEIGHT

12.125 lb

HOSPITAL NAME

Our House Call Vet

REFERRING VET

Dr. Mazzola